

Neurotoxicity and hypertension following European adder (*Vipera berus berus*) bites in Hungary: case report and review

T. MALINA¹, L. KRECSAK² and D.A. WARRELL³

From the ¹Department of Systematic Zoology and Ecology, University of Szeged, Dugonics tér 13, H-6722 Szeged, ²Department of Systematic Zoology and Ecology, Eötvös Loránd University, Pázmány Péter s. 1/C, H-1117 Budapest, Hungary and ³Nuffield Department of Clinical Medicine, University of Oxford, John Radcliffe Hospital, Oxford OX3 9DU, UK

Introduction

In Europe, the common adder (*Vipera berus*) is extensively distributed and causes more bites than any other species in the genus *Vipera*.¹ In Hungary, there are two subspecies; the nominate form (*V. b. berus*) in the East and Northeast and the Bosnian adder (*V. b. bosniensis*) in the Southwest (Figures 1 and 2).²

Envenomings by *V. berus* result in characteristic systemic symptoms including early 'anaphylactic' features such as tachycardia, dizziness, hypotension, shock and gastrointestinal symptoms, coagulopathy and neutrophil leucocytosis.^{1,3,4} These symptoms resemble those caused by *V. aspis*, reflecting the similarities in the composition of their venoms.⁵ Systemic neurotoxicity has been described in patients envenomed by certain populations of some subspecies of *V. aspis* and *V. ammodytes* in Europe.⁶ It has been attributed to pre-synaptic (ammodytoxins) or post-synaptic neurotoxic phospholipases A₂ (PLA₂) in their venoms.⁶ However, neurotoxicity is a most unusual and unexpected clinical feature of *V. berus* envenoming. We describe here a case from eastern Hungary with other interesting features and review the scanty and somewhat obscure literature on this phenomenon.

Case report

A previously healthy 27-year-old man was bitten by an adult female *V. berus* 70–72 cm in total length on 23 April 2007 in Szabolcs–Szatmár–Bereg County in

eastern Hungary (Figure 2). The snake was captured alive and expertly identified. The victim reported no previous snakebites. Two fangs impaled the left thumb, causing burning pain that became throbbing in quality. The bitten finger swelled immediately and a small haematoma formed at the bite site. Swelling associated with erythema extended to the hand in 45 min. The patient applied a tourniquet around the proximal phalanx of the thumb and the wrist, which was released every 15–20 min. It was still in place when he was admitted. Within ~90 min, he was transported to the nearest hospital.

On admission, the patient was fully conscious. He had two attacks of profuse diarrhoea and one episode of mild nausea. Examination revealed tense, tender swelling involving the whole hand and wrist. Erythema was mild and local haemorrhage was confined to the fang marks, which were clearly visible. He was unable to move his fingers or make a fist. He had been slightly nauseated and dizzy during the journey. On arrival at hospital he felt 'drugged' although he had taken no medications except two 500 mg calcium tablets. After 20–30 min, he suddenly noticed double vision; his gaze seemed to shift horizontally and there was a dim ghost image. He became increasingly dizzy and experienced true vertigo when he lay supine. On examination, there was no ptosis but diplopia was confirmed. There was definite strabismus and the second image disappeared when one eye was covered. His gait was found to be unsteady.

Address correspondence to T. Malina, Department of Systematic Zoology and Ecology, University of Szeged, Dugonics tér 13, H-6722 Szeged, Hungary. email: dyspholidus@gmail.com




Figure 1. Common adders (*Vipera berus*) from Hungary: (a and b) *V. b. berus*, female specimens from the population where our patient was bitten (Vámosatya, Szabolcs–Szatmár–Bereg County, E Hungary) (Photographs Tamás Malina). (c) *V. b. bosniensis* female from Darvaspuszta, Somogy County, SW Hungary (Photographs Zoltán Korsós).

There was no nystagmus and the pupils were moderately dilated, equal in size and reactive to light and accommodation. There was mild fever (37.6°C). When he was first examined, 1.5 h after the bite, the heart rate was increased (103/min) and the blood pressure was elevated to 180/120 mmHg. This hypertension was controlled

with captopril 12.5 mg. The blood pressure decreased to 150/90 mmHg over the next few hours, but was still 139/82 mmHg the next morning. According to the patient, his blood pressure is usually about 118/79 mmHg with a heart rate of 65/min. At this stage, 2 h after the bite, he was given tramadol 50 mg i.v. ~1–2 h later, he began to feel drowsy. On admission to hospital, his differential leucocyte count was mildly abnormal: absolute neutrophils count $9.59 \times 10^9/l$, 84.5% (normal: 42–74%), lymphocytes 9.9% (normal: 17–45%), eosinophils 0.5% (normal: 1–7%). Blood coagulation and urine were normal.

Although antivenom is indicated when neurological and/or other systemic symptoms evolve,^{1,3} it was not given in this case because the patient feared a reaction. The neurological signs were not considered life-threatening. Diplopia lasted for 11 h after the bite and then resolved spontaneously, while intense dizziness gradually wore off within 2 days. The dorsum of the hand was slightly bluish in colour until the third day. The moderate local swelling was receding by the fourth day. Tender arthralgia of metacarpal and interphalangeal joints of the bitten hand lasted for 8 days.

Discussion

Neurotoxic effects of *V. berus* envenoming are poorly documented in the literature. Subjective symptoms such as the respiratory distress and paraesthesiae cited by certain authors, are far too non-specific to be acceptable as evidence of neurotoxic envenoming.¹ Patients severely envenomed by *V. berus* may become unconscious,^{4,7} but this is attributable to the early, profound, persistent or recurrent hypotension that is such a marked clinical feature of these envenomings. Coma certainly does not imply a central neurotoxic effect of the venom that would be inherently implausible since the molecular size of snake venom neurotoxins allows minimal penetration of the blood–brain barrier.⁸ ‘Lip paralysis’ is readily confused with angioedema, a characteristic feature of *V. berus* bite,¹ and should not be considered a neurological sign.⁷

Only one case of cranial nerve disturbances following *V. berus* envenoming has been described in the literature. In Poland, bilateral ptosis and blurred vision developed in a case of *V. b. berus* bite.⁹ Ptosis is the classical early sign of snakebite neurotoxicity, while blurred vision resulting from impaired visual accommodation is also a familiar feature of neurotoxic envenoming.⁴ In these *V. berus* populations, the presence of venom

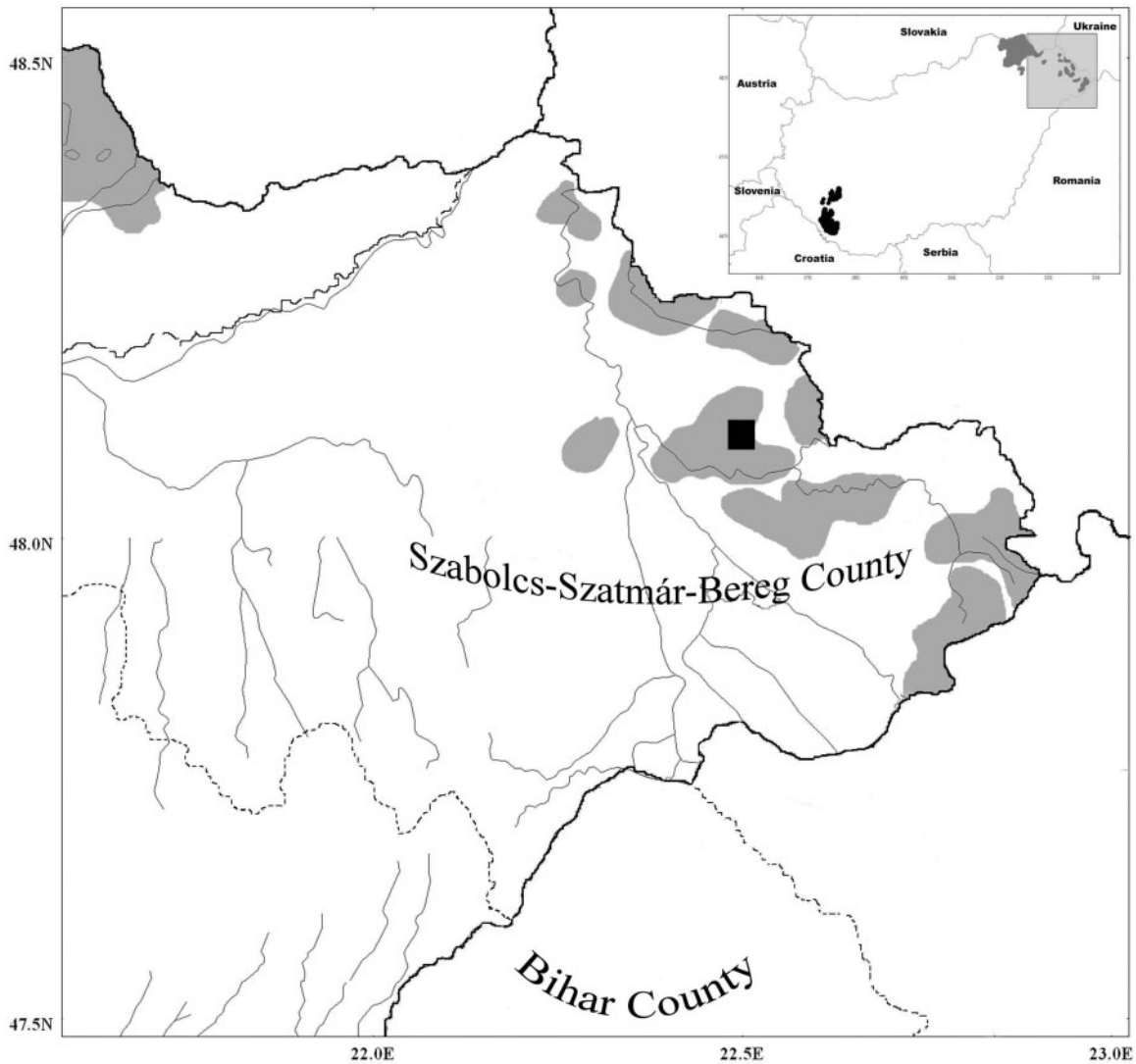


Figure 2. Distribution of *Vipera berus* populations are shown by grey shaded areas in eastern Hungary. The black square is the location of the present case described. Legend: *Vipera berus berus* populations are marked by grey shading, *V. b. bosniensis* by black shading.

neurotoxins is strongly suspected on the basis of these symptoms. Another report, of permanent partial left ptosis and persistent left facial nerve palsy following a bite in the left fronto-temporal area by *V. b. berus* in northern Germany,¹⁰ was explained by direct local effects of the venom and associated gross swelling of the face, orbit and eyelid rather than by systemic neurotoxicity.

We were able to find two further cases of cranial nerve disturbances after envenoming by *V. berus* in older Hungarian medical literature. In Bihar County (western Transylvania, Romania), where only *V. b. berus* occurs, a 43-year-old woman developed ophthalmoplegia¹¹, and a 24-year-old man developed bilateral ptosis and blindness lasting for 2 days.¹² Antivenom was given in neither case, but they recovered in 13 and 4 days, respectively.^{11,12}

These cases are of particular relevance because Szabolcs–Szatmár–Bereg County, where our patient was bitten, is close to Bihar County (Figure 2).

Studies of *V. b. berus* venom have revealed antihemostatic and myotoxic activity.^{13,14} There is, so far, no reliable report of neurotoxic activity in *Vipera berus* venom. Early laboratory studies suggested that venoms of certain German *V. b. berus* populations might be neurotoxic, but this has never been confirmed experimentally or clinically.¹⁵ Križaj *et al.*¹⁶ cited a personal communication by Alan Harvey that no neuromuscular blocking activity could be detected on chick biventer cervicis preparation in *V. b. berus* venom of Russian origin. Ramanazova *et al.*¹⁷ were unable to demonstrate neurotoxin in the venom of *V. b. berus*. Other authors have also concluded that the venom of this

Table 1 Clinical symptoms suggesting activity of snake venom neurotoxins that have been observed so far in patients envenomed by different taxa

Taxa	Neurotoxins found in the venom	Ptosis	Ophthalmoplegia ± diplopia	Blurred vision	Dysphagia	Dysphonia
Genus: <i>Vipera</i>						
<i>V. ammodytes ammodytes</i>	+	+	+	+	+	–
<i>V. a. meridionalis</i>	+	+	+	–	+	–
<i>V. aspis aspis</i>	–	–	–	–	–	–
<i>V. a. aspis</i> (in SE France)	+	+	+	–	+	–
<i>V. a. zinnikeri</i>	+	+	+	–	+	–
<i>V. a. francisciredi</i>	+	–	–	–	+	+
<i>V. berus berus</i>	–/?	#	Pw	#	–	–
<i>V. b. bosniensis</i>	±	+	+	–	–	–
Genus: <i>Daboia</i>						
<i>D.siamensis</i> (Taiwan)	+	+	+	–	–	–

+: detected/observed; –: not detected/not observed; ±: most probably present;

?: questionable in certain populations; Pw: recorded in the present work; #: observed but cannot be attributed to neurotoxicity *per se* (Weinelt *et al.*,¹⁰; Ciszowski and Modla⁹).

species lacks neurotoxic properties.^{6,7,18} However, in the venom of the Bosnian adder (*V. b. bosniensis*), neurotoxicity is more prominent than antihemostatic effects.¹⁹ This is consistent with the clinical features, such as ptosis and ophthalmoplegia, exhibited by humans envenomed by *V. b. bosniensis* as documented by Reuss.²⁰ Neurotoxin encoding genes (i.e. A and B chain of Vaspin) have been demonstrated in one population of *V. b. berus* in Central France,^{21,22} but these genes are either not expressed or expressed only very weakly, as neurotoxic proteins do not appear in the venom and, consequently, neurological symptoms do not evolve in bitten patients.²¹

After ptosis, diplopia resulting from paralysis of extra-ocular muscles is usually the next effect of the descending paralysis typical of snakebite neurotoxicity. Ours is the first clinical report of this feature after *V. b. berus* envenoming but it has been observed, together with other neurological signs such as ptosis, ophthalmoplegia and dysphagia, following bites by some populations of *V. aspis* and *V. ammodytes*, whose venoms are known to contain neurotoxins.^{7,22} (Table 1). Our patient's diplopia resolved rapidly, 11 h after the bite, suggesting that it was caused by a postsynaptic neurotoxin (i.e. Vaspin) in the venom of this *V. b. berus* population. Clinical effects of postsynaptic neurotoxins tend to resolve more rapidly than those caused by presynaptic neurotoxins which damage the nerve terminals. We presume that the neuromuscular junctions innervating the extraocular muscles (*m. rectus*, *m. obliquus*) were reversibly blocked by venom neurotoxin causing external

ophthalmoplegia and hence double vision, which resolved when the neurotoxin dissociated from its receptor.

Drowsiness is a puzzling and unexplained feature of neurotoxic and other snakebites,⁷ but in our patient this may have been attributable to the analgesic he had been given. Neurotoxicity and the resulting diplopia, dizziness or high blood pressure may have contributed to our patient's dizziness, positional vertigo and unsteady gait.

Our patient showed another extraordinary sign, pronounced and protracted high blood pressure as opposed to hypotension, which is the most dangerous effect of *V. berus* envenoming.^{1,3,4} In a case of *V. b. bosniensis* bite in south-western Hungary in 1979, an abnormally high blood pressure was recorded (200/120 mmHg), which peaked 32 h after the bite. This patient also developed bilateral ptosis (Dr Miklós Lőke, personal communication). However, apart from that case, we could find no records of hypertension and tachycardia following European *Vipera* bites, except in a 6-year-old boy in Denmark who developed high blood pressure secondary to renal damage.²³ Anxiety can raise the blood pressure, but our patient denies that he was anxious on admission. His high blood pressure fluctuated, responded promptly to the angiotensin-converting enzyme vasodilator captopril, but later recurred. It has been suggested that the venom of certain *V. berus* population might contain cardiotoxins,¹ capable of acting at autonomic synapses to affect blood pressure.

Hypertension without neurotoxic symptoms was observed in patients envenomed by Western

Russell's vipers (*D. siamensis*) in Taiwan.²⁴ Neuro-myotoxic signs caused by bites of Eastern Russell's vipers (*D. russelii*) and attributable to PLA₂ neurotoxins in Sri Lanka and India are not associated with hypertension (Table 1).⁴ It seems likely, therefore, that distinct toxins are responsible for these neurological and cardiovascular symptoms. Scorpion ion channel toxins release noradrenaline, dopamine and other catecholamines causing hypertension with tachycardia as seen in human victims of envenoming by *Androdoctonus* spp., *Leiurus quinquestriatus* and other taxa.²⁵ Perhaps a venom constituent of this *V. b. berus* population releases catecholamines from adrenergic nerve endings to cause similar effects on blood pressure.

Some authors suppose that Vaspin genes may occur in all the species of Palaearctic vipers.²² Ammodytoxin genes have been demonstrated in different viperid species from south-eastern France to Slovenia.²² It seems likely that Vaspin genes are expressed in the populations of *V. b. berus* in eastern Hungary, while the venom of *V. b. bosniensis* in south-western Hungary may contain Ammodytoxins, as well. The presence of Ammodytoxins would support the hypothesis of some Hungarian authors' that Slovenia is a possible origin of this population.² Alternatively, the neurotoxic activity of the venom of eastern Hungarian *V. b. berus* populations may have evolved in parallel with *V. b. bosniensis* populations in the Balkans, or have been retained after the recolonisation from the Balkans, since the Balkan Peninsula was a possible refugia.²² This could explain the occurrence of neurotoxicity after bites by *V. b. berus* in Bihar County, which is close to the area where our patient was bitten. Fortunately, there is so far no suggestion that neurotoxic envenoming by *V. berus* populations or by any other European *Vipera* is in itself life-threatening.

In conclusion: (i) Venom composition is probably highly variable among the different populations throughout the area of distribution of *V. berus*. (ii) Neurotoxins such as Vaspin are presumably present in certain *V. b. berus* populations in Hungary. (iii) We hypothesize that these toxins are atavistic constituents of the *berus*-toxin, which disappeared from the venom of the other *V. b. berus* population during venom evolution.

Acknowledgements

We thank the András Jóna Hospital of Nyíregyháza (E Hungary), which permitted the publication of this case. We are grateful to Dr Andrea Czvikli (Neurology and Psychiatry, Municipal Hospital of

Komlós, Hungary) and Dr Christine Karlson-Stiber (Karolinska Hospital, Stockholm, Sweden) for their valuable comments on the manuscript. The authors also thank Dr Miklós Lóke (Municipal Hospital of Nagyatád, SW Hungary) for his personal communication of a case of a *V. b. bosniensis* bite and Dr Zoltán Korsós (Hungarian Natural History Museum) for the *V. b. bosniensis* photograph.

Conflict of interest: None declared.

References

1. Karlson-Stiber C, Salmonson H, Persson H. A nationwide study of *Vipera berus* bites during one year – Epidemiology and morbidity of 231 cases. *Clin Toxicol* 2006; **44**:25–30.
2. Korsós Z, Krecsák L. Taxonomy and ecology of the Hungarian populations of the Common adder (*Vipera berus*). *Programme and Abstracts: Fifth World Congress of Herpetology* 19–24 June 2005, South Africa, Stellenbosch, 136–7.
3. Warrell DA. Treatment of bites by adders and exotic venomous Snakes. *BMJ* 2005; **331**:1244–7.
4. Warrell DA. Injuries, envenoming, poisoning, and allergic reactions caused by animals. In: Warrell DA, Cox, TM, Firth JD, Benz EJ, eds. *The Oxford Textbook of Medicine*, 4th edn. Oxford, Oxford University Press, 2003; **1**:923–51.
5. Jan V, Maroun RC, Robbe-Vincent A, Haro de L, Choumet V. Toxicity evolution of *Vipera aspis aspis* venom: identification and molecular modelling of a novel phospholipase A₂ heterodimer neurotoxin. *FEBS* 2002; **527**:263–8.
6. Ferquel E, Haro de L, Jan V, Guillemain I, Jourdain S, Teynié A, et al. Reappraisal of *Vipera aspis* venom neurotoxicity. *PLoS ONE* 2007; **11**:1–18.
7. Meier J, Rauber-Lüthy C, Kupferschmidt H. Aspispviper (*Vipera aspis*) und Kreuzotter (*Vipera berus*): die medizinisch bedeutsamen Giftschlangen der Schweiz 2. Teil: Vorbeugung, Erste Hilfe und Behandlung von Bissunfälle. *Schweiz Med Forum* 2003; **34**:780–5.
8. Gubenšek F, Ritonja A, Cotič V, Kozelj G, Pihler B, Oresković D, et al. Distribution of *Vipera ammodytes* toxic phospholipase A₂ in the cat and its ability to cross the blood-brain barrier. *Toxicon* 1982; **20**:191–4.
9. Ciszowski K, Modla A. Envenoming by the Common viper (*Vipera berus*) – subject still exist. *Przeg Lek* 2004; **61**: 427–32 (In Polish) (Abstract in English).
10. Weinelt W, Sattler RW, Mebs D. Persistent paresis of the facialis muscle after European adder (*Vipera berus*) bite on the forehead. *Toxicon* 2002; **40**:1627–9.
11. Petraskó I. Snakebite envenomings and our native venomous snakes. Temesvár, *Uhrmann Henrik Könyvny* 1899; 3–36
12. Széll L. Snakebite – treated with ammoniac. *Gyógyászat* 1878; **36**:525–8 (In Hungarian).
13. Boffa GA, Boffa MC, Winchenne JJ. A phospholipase A₂ with anticoagulant activity I. Isolation from *Vipera berus* venom and properties. *Biochim Biophys Acta* 1976; **429**:828–38.

14. Calderón L, Lomonte B, Gutiérrez JM, Tarkowski A, Hanson LA. Biological and biochemical activities of *Vipera berus* (European viper) venom. *Toxicon* 1993; **31**:743–54.
15. Otto R. Untersuchungen über die Toxine europäischer Vipereinen. *Z Hyg* 1929; **110**:82–92.
16. Križaj I, Siigur J, Samel M, Cotič V, Gubenšek F. Isolation, partial characterization and complete amino acid sequence of the toxic phospholipase A₂ from the venom of the common viper, *Vipera berus berus*. *Biochim Biophys Acta* 1993; **1157**:81–5.
17. Ramazanov AS, Zavada LL, Starkov VG, Kovyazina IV, Subbotina TF, Kostyukhina EE, et al. Heterodimeric neurotoxic phospholipase A₂ – the first proteins from venom of recently established species *Vipera nikolskii*. Implication of venom composition in viper systematics. *Toxicon* **51**:524–37.
18. de Haro L, Robbe-Vincent A, Saliou B, Valli M, Bon C, Choumet V. Unusual neurotoxic envenomations by *Vipera aspis aspis* snakes in France. *Hum Exp Toxicol* 2002; **21**:137–45.
19. Schöttler WHA. Die Gifte von *Vipera latasti* und *Vipera lebetina*. *Z Hyg Infektionskr* 1938; **120**:408–34.
20. Reuss FAT. Observations of four species of European Toxicophidia. *Comptes Rendus du XIIe Congrès International de Zoologie – Lisbonne* 1937; 1787–1804.
21. Guillemin I, Bouchier C, Garrigues T, Wisner A, Choumet V. Sequences and structural organization of phospholipase A₂ genes from *V. aspis aspis*, *V. aspis zinnikeri*, and *Vipera berus berus* venom. Identification of the origin of a new viper population based on ammodytin I1 heterogeneity. *Eur J Biochem* 2003; **270**:2697–706.
22. Jan VM, Guillemin I, Robbe-Vincent A, Choumet V. Phospholipase A2 diversity and polymorphism in European viper venoms: Paradoxical molecular evolution in Viperinae. *Toxicon* 2007; **50**:1140–61.
23. Krue S, Hansen KN. Transient arterial hypertension following an adder bite in a six-year-old boy. *Ugeskr Laeger* 1999; 161:49–50 (In Danish) (Abstract in English).
24. Hung D-Z, Wu M-L, Deng J-F, Yang D-Y, Lin-Shiau S-Y. Multiple thrombotic occlusions of vessels after Russell's viper envenoming. *Pharm Toxicol* 2002; **91**:106–10.
25. Ismail M. The scorpion envenoming syndrome. *Toxicon* 1995; **33**:825–58.